



Open Access

ORIGINAL ARTICLE

Prostate Diseases

Outcome of nephrostomy balloon dilation for vesicourethral anastomotic strictures following radical prostatectomy: a retrospective study

Chong-Yu Zhang^{1*}, Yu Zhu^{1*}, Kin Li², Laphong Ian², Sonfat Ho², Waihong Pun², Hiofai Lao², Vitalino Carvalho², Ding-Yi Liu³ and Zhou-Jun Shen¹

To evaluate the efficacy of nephrostomy balloon dilation (NBD) for patients who developed vesicourethral anastomotic stricture (VAS) following radical prostatectomy. NBD was performed in patients who developed VAS following radical prostatectomy. Quality of life (QoL), International Prostate Symptom Score (IPSS) and maximal urinary flow rate (Q_{max}) were evaluated. Four hundred and sixty-three prostate cancer patients underwent radical retropubic prostatectomy (RRP), and 86 underwent laparoscopic radical prostatectomy (LRP). Most patients (90.3%) had T2 or T3 prostate cancer and a pathological Gleason score of ≤ 7 . Forty-five (8.2%) and four (4.7%) patients developed VAS due to radical or LRP, respectively. Forty (89%) patients underwent NBD, including three cases of repeat dilation. The median Q_{max} was 4 ml s⁻¹ (interquartile range (IQR), 2.3–5.6) before dilation and improved to 16 ml s⁻¹ (IQR, 15–19) and 19 ml s⁻¹ (IQR, 18–21) at the 1- and 12-month follow-up, respectively ($P < 0.01$). Fifteen (37.5%) patients had urinary incontinence prior to dilation, whereas only three (7.5%) patients had incontinence 12 months following dilation ($P < 0.01$). The median IPSS score improved from 19 (IQR, 17–24) before dilation to 7 (IQR, 6–8) at 12 months following dilation, and the QoL score improved from 5 (IQR, 4–6) before dilation to 2 (IQR, 2–3) at 12 months following dilation ($P < 0.01$ in both). VAS occurs in a small but significant proportion of patients following radical prostatectomy. NBD offers an effective remedy for VAS.

Asian Journal of Andrology (2014) 16, (115–119); doi: 10.4103/1008-682X.122348; published online: 16 December 2013

Keywords: nephrostomy balloon dilation (NBD); quality of life (QoL); radical prostatectomy; vesicourethral anastomotic stricture (VAS)

INTRODUCTION

Radical prostatectomy remains a common option for clinically localized prostate cancer. A recent competing-risks analysis¹ of a large North American population-based cohort indicates that, relative to observation, radical prostatectomy reduces the risk of cancer-specific mortality by half in patients aged ≥ 65 years. Radical prostatectomy involves removal of the prostate, including its fibrous capsule, the surrounding fat and the seminal vesicles. After removal of the prostate, the bladder neck is reconstructed and tapered to a diameter consistent with that of the urethra, and a vesicourethral anastomosis is created. Surgical experience suggests that the procedure is generally safe, but the development of a stricture at the vesicourethral anastomosis is a significant complication.

The incidence of vesicourethral anastomotic stricture (VAS) varies from 0.48% to 32%.^{2–4} The narrowing may result in significant bladder outlet obstruction symptoms, including poor urine stream, urgency, incomplete bladder emptying and even eventual acute urinary retention in a minority of patients. Urinary extravasation, intraoperative blood loss and a prior history of transurethral surgeries have traditionally been implicated as risk factors for anastomotic stricture. Furthermore, surgical techniques, previous radiotherapy

and microvascular diseases may also play a role in the development of anastomotic strictures.⁵

Currently, various procedures exist for managing anastomotic strictures^{2,5–8} after radical prostatectomy, including single sounds or balloon dilation, cold knife incision, transurethral resection or internal urethrotomy with a Holmium laser. However, none of these methods is universally accepted due to the relatively high recurrence rate. In addition, a subset of anastomotic strictures following radical prostatectomy is recurrent and recalcitrant to standard endoscopic therapy. In the current study, we retrospectively reviewed the surgical outcome and safety of 549 clinically localized prostate carcinoma patients who received radical prostatectomy at three tertiary care institutions in China. Furthermore, we evaluated the efficacy of nephrostomy balloon dilation (NBD) for patients who developed a VAS following radical prostatectomy with the International Prostate Symptom Score (IPSS), quality of life (QoL) score and urinary continence as the primary endpoints.

PATIENTS AND METHODS

Subjects

We retrospectively reviewed the clinicopathologic and surgical data

¹Department of Urology, Ruijin Hospital, Shanghai Jiaotong University School of Medicine, Shanghai, China; ²Department of Urology, Conde S. Januário Hospital Centre, Macao, China; ³Department of Urology, Pu Nan Hospital, Shanghai, China

* These authors contributed equally to this work.

Correspondence: Dr. ZJ Shen (shenzj6@sina.com)

Received: 09-06-2013; Revised: 21-07-2013; Accepted: 01-09-2013

of prostate carcinoma patients who received radical retropubic prostatectomy (RRP) or laparoscopic radical prostatectomy (LRP) between January 2007 and March 2010 at three major metropolitan general hospitals in China. All the institutions had implemented good clinical practice. The study protocol was approved by local ethical committees and institutional review boards at the participating institutions. Informed consent was not required because of the retrospective nature of the study. Prostate cancer was pathologically confirmed and classified by the tumor-node-metastasis (TNM) system according to the American Joint Committee on Cancer (AJCC).⁹ The major inclusion criteria were a prostate-specific antigen (PSA) value $<50 \text{ ng ml}^{-1}$, an age ≤ 75 years, negative bone scan for metastatic disease, and a life expectancy of at least 10 years from the time of surgery.

Surgical techniques

Radical retropubic prostatectomy

RRP was performed as previously described.^{10,11} The prostate and seminal vesicles were removed, and the bladder neck was preserved at the surgeon's discretion. The bladder neck was reconstructed, the mucosa was everted and a direct mucosa-to-mucosa anastomosis between the bladder neck and urethra was made by six interrupted 3-0 monocryl/polyglactin sutures over a 16F silicone Foley catheter or a 22-24F 3-way Foley catheter. Alternatively, after bladder neck preservation, vesicourethral anastomosis was performed using the running suture technique with 3-0 polyglactin, as was performed in LRP.

Laparoscopic radical prostatectomy

LRP was performed using the antegrade Montsouris technique.¹² After the removal of the prostate and seminal vesicles, a posterior running suture of 3-0 polyglactin was used to approximate full-thickness muscularis and mucosa, forming a tennis racket closure when the bladder neck was reconstructed. The neck was narrowed to approximate the diameter of the urethra. Beginning at the posterior wall, a U-shaped suture was placed from the inside to the outside at the bladder level, from the outside to the inside of the lumen of the urethra, from the inside to the outside of the lumen of the urethra and finally from the outside to the inside of the lumen of the bladder. The double-looped knot, placed inside the bladder neck, was spontaneously self-blocked due to tension applied to the threads, allowing the bladder and urethra to be approached simultaneously. Two sets of lateral sutures alternating at the 5, 7, 2 and 10 O'clock position with the knot on the outside were introduced. This U-shape suture was also used to close the bladder neck anteriorly. A silicone 16F Foley catheter was introduced through the anastomosis to reach the bladder.¹⁰

Nephrostomy balloon dilation

NBD was performed under local or spinal anesthesia for patients who developed a VAS following radical prostatectomy. A 0.035-inch guide wire (Amplatz Super Stiff; Boston Scientific, Natick, MA, USA) was inserted through a flexible cystourethroscope into the bladder, followed by advancing a 15-cm nephrostomy balloon (Ultraxx Nephrostomy Balloon; Cook Urological, Spencer, IN, USA) over the guide wire. When the balloon reached the bladder distally and the bulbous urethra proximally, as indicated by radiopaque strips on both ends of the balloon, it was inflated to 30F in circumference with a 37% contrast agent by an inflation device (Sphere Inflation Device; Atrion Medical, Arab, AL, USA) (Figure 1). After a 15-min balloon dilation, the anastomosis

was examined under a flexible cystourethroscope (Figure 2), and a 24F Foley catheter was left indwelling for 7 days. The operation was performed by four similarly experienced surgeons at the three participating institutions.

Clinical evaluation

A physical examination including a digital rectal examination of the prostate and laboratory studies including PSA were performed at baseline and at subsequent onsite visits at 1, 3, 6 and 12 months postoperatively. Lower urinary tract symptoms, symptom-specific QoL and IPSS (score range: 0-35; mild 0-7, moderate 8-19 and severe >20) were evaluated for efficacy of treatment. Bone metastases were documented on the basis of positive results from bone scanning or skeletal radiography. We also evaluated 30-day perioperative adverse events. VAS was suspected in patients with a significant reduction of the maximal urinary flow rate ($Q_{\max} < 10 \text{ ml s}^{-1}$) and a post void residual volume $>150 \text{ ml}$ and confirmed by flexible cystourethroscopy. Recurrence of the anastomotic stricture was considered when Q_{\max} went below 10 ml s^{-1} after NBD. Urinary continence status was investigated with the 1-h pad test according to the International Continence Society recommendations.⁹

Study endpoints

The primary endpoints of this retrospective review were the efficacy of the NBD as evidenced by an improvement in the IPSS and QoL scores, Q_{\max} and urinary continence. Secondary outcomes included PVR and major urinary events. These parameters were measured at baseline and 1, 3, 6 and 12 months postoperatively. Major urinary events included acute urinary retention and gross hematuria. Other adverse events were also recorded at baseline and at subsequent follow-up visits.

Statistical analysis

Data were reported as the mean, interquartile range (IQR), and standard deviation or frequency and percentage for continuous and categorical variables, respectively. We used the two-sided *t*-test to compare continuous variables and used the Fisher's exact test and Pearson χ^2 test to compare categorical variables. Paired differences between the pre- and post-dilation urinary function data were assessed with the Wilcoxon signed rank test. $P < 0.05$ was considered statistically

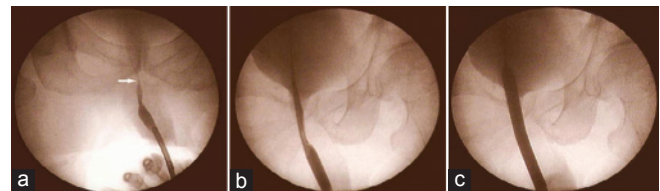


Figure 1: (a) Urethrography shows a vesicourethral anastomotic stricture (white arrow). (b) The dilation balloon was inflated with contrast material. (c) The dilation caliber reaches 30 F when the pressure in the balloon is 20 atm

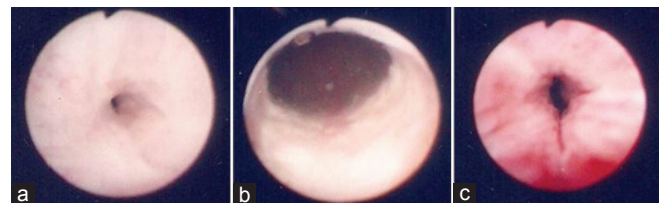


Figure 2: (a) The pinhole stricture of the vesicourethral anastomosis. (b) Vesicourethral anastomosis after dilation with a 30 F balloon. (c) The external sphincter is intact after balloon dilation

significant. All statistical analyses were performed using Statistical Analysis Software v. 9.2 (SAS Institute, Cary, NC, USA).

RESULTS

Demographic and baseline characteristics of study participants

Five hundred and forty-nine prostate cancer patients undergoing RRP or LRP at participating institutions were included in the study. The demographic and disease characteristics are shown in **Table 1**. The median age at surgery was 66 years (IQR, 63-68 years). Their median preoperative PSA level was 8.7 ngml⁻¹ (IQR, 6.6-13.2 ng ml⁻¹). Most patients (90.3%) had T2 or T3 prostate cancer, and the great majority of them (90.3%) had a pathological Gleason score of ≤7. In addition, 63.8% of the patients had low-risk, 27.9% had intermediate-risk and 8.3% had high-risk prostate cancer.

Surgical outcomes

Four hundred and sixty-three patients received RRP and 86 patients underwent LRP. The surgical characteristics of the study cohort are shown in **Table 2**. The mean operative time was 149 ± 47.1 min, and the estimated volume of blood loss was 313.8 ± 121 ml. The median length of catheterization was 12.2 days (IQR, 8.3-15.7). Eighty-nine (16.2%) patients had positive surgical margins. We further stratified the surgical outcome of these patients by anastomotic sutures. The mean operative time for patients receiving interrupted sutures (132 ± 26.4 min) was noticeably shorter than that for patients receiving running sutures (193 ± 32.1 min) (*P* < 0.05). Patients receiving interrupted sutures and those receiving running sutures were comparable in demographic and baseline characteristics, length of catheterization, intraoperative blood loss, anastomotic time and the rate of positive surgical margins (**Table 3**).

Surgical morbidities

Perioperative complications during the first 30 days after surgery occurred in 31.3% of the patients who underwent radical prostatectomy and included four deaths. The most common complication was prolonged (>14 days) anastomotic leakage (9.7%), followed by prolonged (>14 days) hematuria (3.8%) and wound dehiscence (3.3%) (**Table 4**). Complications occurring in at least 2% of the patients included pelvic lymphorrhoea (2.4%) and inguinal hernia (2.0%). Acute urinary retention occurred in 0.4% of the men.

Rates of anastomotic stricture

Forty-five (8.2%) patients developed a VAS with a median time of 4.1 months (IQR, 3.1-6.7 months) from RRP. Four (4.7%) patients receiving LRP developed an anastomotic stricture. Thirty-nine (10.1%) patients with interrupted sutures and six (3.7%) patients with running sutures developed an anastomotic stricture (**Figure 3**). To determine whether the difference between these two proportions was statistically significant, we used a *z*-test of independent proportions. This yielded a *z*-score of 1.78 (*P* < 0.001), suggesting that patients who have their vesicourethral anastomoses constructed with the interrupted suture technique are more likely to have anastomotic strictures than patients with running sutures.

Outcome of NBD for VASs

Forty (89%) patients underwent NBD, and three (7.5%) of them had repeat dilation due to weak voiding 4, 5 and 9 months after the first dilation. Thereafter, no repeat dilation was required. Three (7.5%) patients received transurethral resection with electrocautery and two (5%) patients had simple dilation only. The median Qmax of patients

Table 1: Demographic and baseline characteristics of the study participants (n=549)

Variable	
Age at surgery, year (median (IQR))	66 (63-68)
BMI, kg m ⁻² (mean±s.d.)	23.1±4.3
Preoperative PSA, ngml ⁻¹ (median (IQR))	8.7 (6.6-13.2)
Clinical stage, n (%)	
T1	23 (4.2)
T2	316 (57.5)
T3	180 (32.8)
T4	30 (5.5)
Pathological gleason score, n (%)	
<7	309 (56.2)
=7	187 (34.1)
>7	53 (9.7)
Tumor risk category (%)*	
Low	350 (63.8)
Intermediate	153 (27.9)
High	46 (8.3)

BMI: body mass index; IQR: interquartile range; PSA: prostate-specific antigen; s.d.: standard deviation. *Low risk=gleason score<6, PSA<10 ngml⁻¹ and tumor stage T1a, T1b, T1c or T2a; intermediate risk=PSA 10.1-20 ngml⁻¹ or Gleason score=7 or stage T2b; high risk=PSA>20 ngml⁻¹ or Gleason score 8-10 or stage T2c

Table 2: Surgical characteristics of the study participants (n=549)

Variable	
Operative time, min (mean±s.d.)	149.9±47.1
Anastomotic time, min (mean±s.d.)	15.61±7.1
Estimated blood loss, mL (mean±s.d.)	313.8±121
Positive surgical margins, n (%)	89 (16.2)
EPE, n (%)	7 (1.3)
SVI, n (%)	15 (2.7)
LNI, n (%)	23 (4.2)
Catheter stay (day), median (IQR)	12.2 (8.3-15.7)

EPE: extraprostatic extension; IQR: interquartile range; LNI: lymph node involvement; SVI: seminal vesicle invasion; s.d.: standard deviation

Table 3: Demographic, baseline and surgical characteristics of the study participants stratified by anastomotic suture techniques

	Interrupted sutures	Running sutures	<i>P</i> value
Age, year (mean±s.d.)	67.1±8.2	64±5.3	0.463
BMI, kg m ⁻² (mean±s.d.)	23.2±3.6	22.8±4.1	0.729
PSA, ngml ⁻¹ (mean±s.d.)	8.9±4.5	8.3±3.9	0.637
Pathologic stage, n (%)			
T1	13 (2.4)	10 (1.8)	0.254
T2	229 (41.7)	87 (15.8)	0.486
T3	125 (22.8)	55 (10)	0.462
T4	21 (3.8)	9 (1.6)	0.231
Operative time, min (mean±s.d.)	132±26.4	193±32.1	0.029
Anastomotic time, min (mean±s.d.)	14.3±2.7	18.8±5.8	0.083
Length of catheterization, d (mean±s.d.)	15.9±2.7	12.6±4.4	0.163
Estimated blood loss, ml (mean±s.d.)	329±107	277±85	0.436
Positive surgical margins, n (%)	58±10.6	31±5.6	0.838

BMI: body mass index, PSA: prostate-specific antigen, s.d.: standard deviation

undergoing NBD was 4 ml s⁻¹ (IQR, 2.3-5.6 ml s⁻¹) before dilation, which improved to 16 ml s⁻¹ (IQR, 15-19 ml s⁻¹) 1 month following surgery (*P* < 0.01). At the last 12-month follow-up, the median Qmax was maintained at 19 ml s⁻¹ (IQR, 18-21 ml s⁻¹) (*P* < 0.01) (**Table 5**).



Fifteen (35%) patients had urinary incontinence prior to dilation, and the number was reduced to three (7.5%) patients 12 months following NBD ($P < 0.01$). Anastomotic stricture patients also experienced a marked improvement in QoL as a result of NBD: the median IPSS score improved from 19 (IQR, 17-24) before dilation to 7 (IQR, 6-8) at 12 months following dilation, and the QoL score improved from 5 (IQR, 4-6) before dilation to 2 (IQR, 2-3) at 12 months following dilation ($P < 0.01$ in both).

DISCUSSION

Excessive intraoperative blood loss, local urinary extravasation and a history of prior transurethral prostatic surgeries are the most often cited predisposing factors for VASs.¹³ Comorbidities such as hypertension, coronary artery disease, diabetes mellitus and cigarette smoking appear to be significant risk factors for the development of anastomotic strictures after radical prostatectomy because these diseases are associated with malfunctioning of the microvascular system and cause local ischemia and scar formation at the anastomosis.⁵ The surgical technique used for bladder neck preservation and the suture material used to create the vesicourethral anastomosis may also contribute to anastomotic strictures.¹⁴ Most

authors are prone to adopting bladder neck preservation to prevent anastomotic strictures.¹⁵⁻¹⁹

In our series, the incidence of anastomotic strictures was 8.2%, which falls within the range of 1%–9.4% reported by others.¹⁵⁻¹⁹ In addition, we found that the incidence of anastomotic strictures was significantly higher in patients with an anastomosis constructed by the interrupted suture technique than in those with the running suture technique. This finding is consistent with those reported by Ozu *et al.*,⁶ who found that the use of running sutures in these patients is safer compared with the use of four to six interrupted sutures, allowing safe early catheter removal in most patients. We speculate that the running suture technique decreases prolonged anastomotic urinary leakage and bleeding, which may lead to local ischemia or blood clot accumulation, delay mucosa healing and result in urinary extravasation. The latter is now considered a potential risk factor for developing an anastomotic stricture.^{7,13}

Currently, there is no commonly accepted therapeutic option for anastomotic strictures. There have been no clinical studies on anastomotic strictures with a large patient sample, and only two studies enrolled more than 50 patients (Table 6). Recommended treatments include simple dilation, transurethral incision or resection of the bladder neck with electrocautery. However, the recurrence rate after the use of these methods is high (Table 6) (42.1%–53.3%),^{2,5} and some patients undergo repeated treatments before they are cured. Scant literature is available on balloon dilation for anastomotic strictures following radical prostatectomy. Kumar and Nargund⁸ used an F15 ureteral balloon catheter as the first-line treatment for anastomotic strictures following radical prostatectomy in nine cases with a balloon inflation pressure of 60 mmHg. The Ultraxx™ Nephrostomy Balloon

Table 4: Adverse events occurring within 30 days after surgery (n=549)

Complications	n (%)
Intraoperative	
Obturator nerve injury	1 (0.1)
Rectal injury	3 (0.5)
Ureteral orifice injury	5 (0.9)
Postoperative (<30 days)	
Death	4 (0.7)
Deep vein thrombosis	3 (0.5)
Anastomotic bleeding	5 (0.9)
Acute urinary retention	2 (0.4)
Anuria	3 (0.5)
Pelvic lymphorrhoea	13 (2.4)
Urethral catheter malfunction	4 (0.7)
Inguinal hernia	11 (2.0)
Pelvic hematoma	9 (1.6)
Pelvic abscess	2 (0.4)
Paralytic ileus	4 (0.7)
Stress ulcer	2 (0.4)
Vesicorectal fistula	2 (0.4)
Pneumonia	7 (1.3)
Wound dehiscence	18 (3.3)
Prolonged (>14 days) anastomotic leakage	53 (9.7)
Prolonged (>14 days) hematuria	21 (3.8)

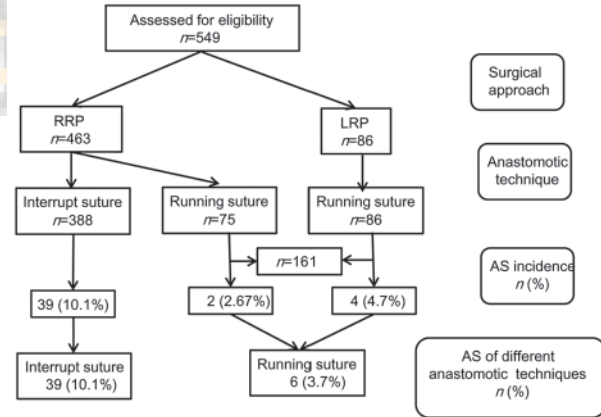


Figure 3: Incidence of vesicourethral anastomotic strictures following radical prostatectomy

Table 5: Urinary function of patients with anastomotic strictures at diagnosis and at subsequent follow-up visits after the last stricture treatment (n=40)

Variable	Predilation	1 month	3 months	6 months	12 months	P value*
Qmax (mls-1), median (IQR)	4 (2.3–5.6)	16 (15–19)	20 (18–21)	19 (18–21)	19 (18–21)	<0.01
IPSS, median (IQR)	19 (17–24)	7 (5–8)	6 (5–7)	6 (5–7)	7 (6–8)	<0.01
QoL, median (IQR)	5 (4–6)	2 (2–3)	2 (2–3)	2 (2–3)	2 (2–3)	<0.01
PVR, median (IQR)	122 (78–142)	51 (37–78)	43 (28–61)	46 (29–62)	45 (24–68)	<0.01
Urinary continence, n(%)						
Yes	26 (65)	31 (77.5)	32 (80)	36 (90)	37 (92.5)	<0.01
No	14 (35)	9 (22.5)	8 (20)	4 (10)	3 (7.5)	<0.01

IPSS: international prostate symptom Score; IQR: interquartile range; Qmax: maximum flow rate; QoL: quality of life; PVR: post-void residual volume; *'pre-dilation' vs. '12months'



Table 6: Management of anastomotic strictures (AS) following radical retropubic prostatectomy reported in the literature

Author	Year	Study cohort (n)	AS, n (%)	Managements		Length of follow-up (month)	No. of recurrences after management, n (%)
				Analyzed methods	n		
Popken <i>et al.</i> ²	1998	340	24 (7.0)	Electrocautery resection	15	12–72	8 (53.3)
Borboroglu <i>et al.</i> ⁵	2000	467	52 (11.1)	Bladder neck incision	14	24	6 (42.9)
Borboroglu <i>et al.</i> ⁵	2000	467	52 (11.1)	Single balloon or urethral sound dilation	38	24	16 (42.1)
Giannarini <i>et al.</i> ²⁰	2008	648	46 (7.1)	Cold-knife incision	43	12	11 (26)
Ramchandani <i>et al.</i> ²¹	1994	357	39 (11)	Balloon dilation	27	12–84	11 (41)
Hayashi <i>et al.</i> ²²	2005	109	15 (13.7)	Holmium laser	3	11–37	0 (0)

is commonly used to dilate the musculofascial tract and renal capsule, establishing a nephrostomy tract during a percutaneous procedure. For access, the balloon has a short transitional taper from the balloon to the catheter shaft at the tip. In our study, this short tip provides a close approximation of the dilating tract to pass the stricture site along the guide wire. Furthermore, depending on the design of the screwed pushing inflation device with a pressure gauge and valve, the pressure inside the balloon could reach 20 atm (15 000 mmHg) and promise success of dilation even if the stricture is quite rigid. In this respect, the nephrostomy balloon set seems more effective than other approaches.^{8,21} Although the external urinary sphincter is close to the vesicourethral anastomosis, with 30F dilation, urinary incontinence is not likely to occur as a potential complication. In our study, we confirmed the integrity of the external sphincter by flexible cystoscopy after dilation. As an inherent advantage, balloon dilation creates only a radial force at the stricture site, whereas standard dilation catheters cause parallel shearing forces. For this reason, the mucosa and elastic sphincter are not easy to injure when the balloon is inflated. Balloon dilation did not impair the urinary continence of our patients in this study. In addition, balloon dilation caused an apparent improvement in the Qmax, IPSS and QoL score.

In conclusion, anastomotic strictures occur in a small but significant proportion (8.2%) of patients following radical prostatectomy. NBD offers an effective remedy for anastomotic strictures with a marked improvement in urinary function and QoL.

REFERENCES

- 1 Abdollah F, Sun M, Schmitges J, Tian Z, Jeldres C, *et al.* Cancer-specific and other-cause mortality after radical prostatectomy versus observation in patients with prostate cancer: competing-risks analysis of a large North American population-based cohort. *Eur Urol* 2011; 60: 920–30.
- 2 Popken G, Sommerkamp H, Schultze-Seemann W, Wetterauer U, Katzenwadel A. Anastomotic stricture after radical prostatectomy: incidence, findings and treatment. *Eur Urol* 1998; 33: 382–6.
- 3 Besarani D, Amoroso P, Kirby R. Bladder neck contracture after radical retropubic prostatectomy. *BJU Int* 2004; 94: 1245–7.
- 4 Augustin H, Pummer K, Daghofer F, Habermann H, Primus G, *et al.* Patient self-reporting questionnaire on urological morbidity and bother after radical retropubic prostatectomy. *Eur Urol* 2002; 42: 112–7.
- 5 Borboroglu PG, Sands JP, Roberts JL, Amling CL. Risk factors for vesicourethral anastomotic stricture after radical prostatectomy. *Urology* 2000; 56: 96–100.
- 6 Ozu C, Hagiuda J, Nakagami Y, Hamada R, Horiguchi Y, *et al.* Radical retropubic prostatectomy with running vesicourethral anastomosis and early catheter removal: our experience. *Int J Urol* 2009; 16: 487–92.

- 7 Kostakopoulos A, Argiropoulos V, Protogerou V, Tekerlekis P, Melekos M. Vesicourethral anastomotic strictures after radical retropubic prostatectomy: the experience of a single institution. *Urol Int* 2004; 72: 17–20.
- 8 Kumar P, Nargund VH. Management of post-radical prostatectomy anastomotic stricture by endoscopic transurethral balloon dilatation. *Scand J Urol Nephrol* 2007; 41: 314–5.
- 9 Abrams P, Cardozo L, Fall M, Griffiths D, Rosier P, *et al.* The standardization of terminology of lower urinary tract function: report from the Standardization Sub-committee of the International Continence Society. *NeuroUrol Urodyn* 2002; 21: 167–78.
- 10 Walsh PC. Anatomic radical prostatectomy. Evolution of the surgical technique. *J Urol* 1998; 160: 2418–24.
- 11 Walsh PC, Mostwin JL. Radical prostatectomy and cystoprostatectomy with preservation of potency. Results using a new nerve-sparing technique. *Br J Urol* 1984; 56: 694–7.
- 12 Guillonnet B, Vallancien G. Laparoscopic radical prostatectomy: the Montsouris technique. *J Urol* 2000; 163: 1643–9.
- 13 Surya BV, Provet J, Johanson KE, Brown J. Anastomotic strictures following radical prostatectomy: risk factors and management. *J Urol* 1990; 143: 755–8.
- 14 Williams SB, Alemozaffar M, Lei Y, Hevelone N, Lipsitz SR, *et al.* Randomized controlled trial of barbed polyglyconate versus polyglactin suture for robot-assisted laparoscopic prostatectomy anastomosis: technique and outcomes. *Eur Urol* 2010; 58: 875–81.
- 15 Soloway MS, Neulander E. Bladder-neck preservation during radical retropubic prostatectomy. *Semin Urol Oncol* 2000; 18: 51–6.
- 16 Kaye KW, Creed KE, Wilson GJ, D'Antuono M, Dawkins HJ. Urinary continence after radical retropubic prostatectomy. Analysis and synthesis of contributing factors: a unified concept. *Br J Urol* 1997; 80: 444–51.
- 17 Poon M, Ruckle H, Bamshad BR, Tsai C, Webster R, *et al.* Radical retropubic prostatectomy: bladder neck preservation versus reconstruction. *J Urol* 2000; 163: 194–8.
- 18 Gaker DL, Steel BL. Radical prostatectomy with preservation of urinary continence: pathology and long-term results. *J Urol* 2004; 172: 2549–52.
- 19 Ramsden AR, Chodak GW. Can leakage at the vesicourethral anastomosis be predicted after radical retropubic prostatectomy? *BJU Int* 2004; 93: 503–6.
- 20 Giannarini G, Manassero F, Mogorovich A, Valent F, De Maria M, *et al.* Cold-Knife Incision of Anastomotic Strictures after Radical Retropubic Prostatectomy with Bladder Neck Preservation: efficacy and Impact on Urinary Continence Status. *Eur Urol* 2008; 54: 647–56.
- 21 Ramchandani P, Banner MP, Berlin JW, Dannenbaum MS, Wein AJ. Vesicourethral anastomotic stricture after radical prostatectomy: efficacy of transurethral balloon dilatation. *Radiology* 1994; 193: 345–9.
- 22 Hayashi T, Yoshinaga A, Ohno R, Ishii N, Watanabe T, *et al.* Successful treatment of recurrent vesicourethral stricture after radical prostatectomy with holmium laser: report of three cases. *Int J Urol* 2005; 12: 414–6.

How to cite this article: Zhang CY, Zhu Y, Li K, Ian L, Ho S, Pun W, Lao H, Carvalho V, Liu DY, Shen Z. Outcome of nephrostomy balloon dilation for vesicourethral anastomotic strictures following radical prostatectomy: A retrospective study. *Asian J Androl* 2013 Dec 16. doi: 10.4103/1008-682X.122348. [Epub ahead of print]